

# Tinel's Sign and Phalen's Maneuver: Physical Signs of Carpal Tunnel Syndrome

*Series Editor and Author: Frank L. Urbano, MD*

**C**arpal tunnel syndrome is a common condition that results from compression of the median nerve at the wrist.<sup>1-3</sup> The syndrome is characterized by pain that begins in the distal arm or wrist and radiates into the thumb, index finger, and middle finger.<sup>3</sup> Patients may also complain of numbness and tingling in the distribution of the median nerve, as well as nocturnal pain, which occurs in as many as 95% of patients.<sup>4</sup> Diagnosis is usually based on clinical grounds but is often confirmed with electrophysiologic testing. Several physical signs are associated with carpal tunnel syndrome, including Tinel's sign and Phalen's maneuver (**Sidebar**). Since the initial description of Tinel's sign and Phalen's maneuver, the significance of these two signs and their usefulness in the diagnosis of carpal tunnel syndrome have been extensively debated.

## HISTORIC PERSPECTIVE

In 1915, German physiologist Paul Hoffman (1884–1962) described a sensation of “tingling” or “pins and needles” that could be elicited whenever an injured nerve was percussed.<sup>5</sup> According to Hoffman, this “distal tingling on percussion” was a sign of nerve regeneration. Later in 1915, Jules Tinel (1879–1952), a French neurologist, described a “tingling sensation” or “formication sign” produced by slight percussion of a nerve trunk some time after an injury.<sup>6</sup> Tinel attributed the tingling to the presence of young axons in the process of growing,<sup>7</sup> thereby validating Hoffman's interpretation of the sign. Although Hoffman first described the symptom, the tingling has been largely recognized as Tinel's sign.

Tinel's sign was not associated with carpal tunnel syndrome until more than 50 years later, when George S. Phalen, an American hand surgeon, described the usefulness of the sign in the diagnosis of this condition.<sup>8</sup> For more than 17 years, Phalen studied patients with carpal tunnel syndrome. In 1957, he described Tinel's sign as “a tingling sensation radiating out into the hand, which is obtained by light percussion over the median nerve at the wrist.”<sup>9</sup> Phalen also

## PHYSICAL SIGNS OF CARPAL TUNNEL SYNDROME

### Tinel's sign

**Elicitation:** Tap over the median nerve as it passes through the carpal tunnel in the wrist

**Positive response:** A sensation of tingling in the distribution of the median nerve over the hand

### Phalen's maneuver

**Elicitation:** Allow wrists to fall freely into maximum flexion and maintain the position for 60 seconds or more

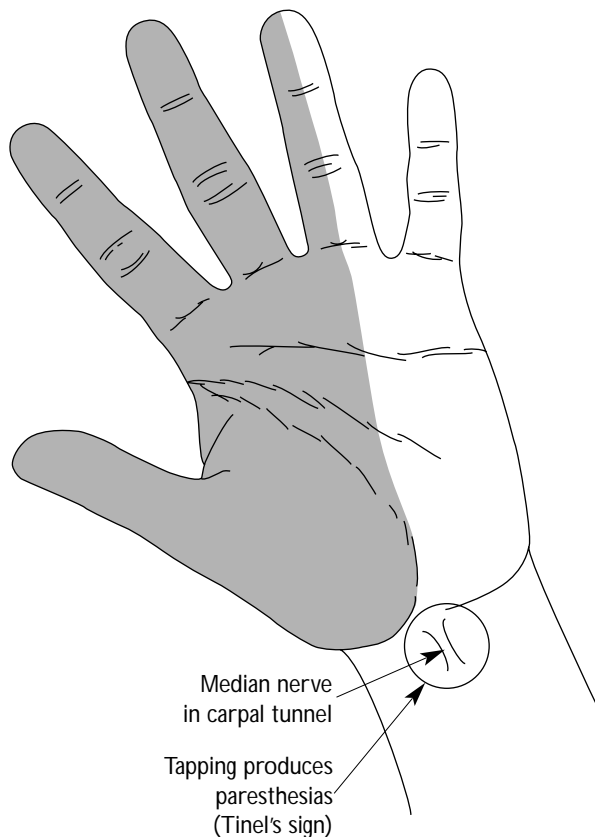
**Positive response:** A sensation of tingling in the distribution of the median nerve over the hand

proposed a diagnostic triad, which included Tinel's sign, a wrist flexion test (ie, Phalen's maneuver), and the appropriate anatomic distribution of paresthesia elicited by both examinations.

## TINEL'S SIGN

As previously noted, the original description of Tinel's sign did not involve carpal tunnel syndrome. The sign has, however, become commonly associated with this condition. A positive Tinel's sign (**Figure 1**) is described as a tingling sensation in a specific anatomic distribution, which occurs as a result of light percussion over a nerve. The intensity of percussion necessary to elicit Tinel's sign should be enough to cause the expected response while avoiding direct mechanical stimulation of the nerve.<sup>6</sup>

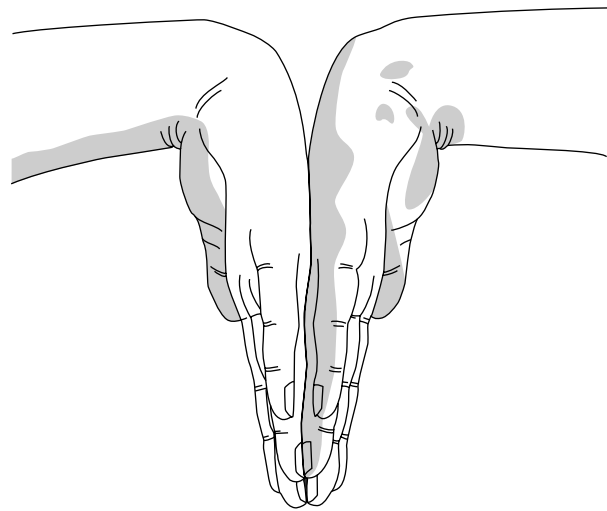
*Dr. Urbano is in general internal medicine, Partners in Primary Care, Medford, NJ.*



**Figure 1.** A positive Tinel's sign for suspected carpal tunnel syndrome results in distribution of paresthesias (shaded area) when the median nerve is compressed by swelling in the wrist. Adapted with permission from Bennett JC, Plum F, eds: *Cecil Textbook of Medicine*, 20th ed. Philadelphia: WB Saunders, 1996:1462.

In suspected carpal tunnel syndrome, the median nerve is percussed, but Tinel's sign may be elicited with percussion of a variety of other nerves, including the radial and peroneal nerves.<sup>5</sup> Other conditions that have been associated with a positive Tinel's sign are cubital tunnel syndrome, radial nerve entrapment, tarsal tunnel syndrome, superficial peroneal neuropathy, and thoracic outlet syndrome.<sup>5</sup> In each case, the positive sign is expressed by percussing the appropriate nerve.

A true Tinel's sign is never painful.<sup>6</sup> Patients may experience a discomfort from the tingling sensation, but the presence of pain with the elicitation of the sign suggests another process occurring concomitantly with the nerve regeneration.



**Figure 2.** A positive response to Phalen's maneuver produces paresthesias in the distribution of the median nerve when hands are held in forced flexion for 60 seconds or more. Adapted with permission from Bennett JC, Plum F, eds: *Cecil Textbook of Medicine*, 20th ed. Philadelphia: WB Saunders, 1996:1463.

### Pathophysiology

The pathophysiology of Tinel's sign is thought to involve abnormal mechanosensitivity of the involved nerve, presumably due to the disease process.<sup>5</sup> This results in afferent discharge at the level of the regenerating nerves, thus producing a pins and needles sensation, which characterizes the sign. On a cellular level, the sign may be caused by an abnormally excitable membrane.

### PHALEN'S MANEUVER

Phalen's maneuver (**Figure 2**), or the wrist flexion test, is described as positive when full flexion of the wrist for 60 seconds causes paresthesia in the territory of the median nerve.<sup>8</sup> The correct performance of the test, as described by Phalen, is to have the patient place flexed elbows on a table, allow the wrists to fall freely into maximum flexion, and maintain this position for at least 1 minute. Patients with carpal tunnel syndrome develop numbness and tingling within 1 to 2 minutes. Healthy patients develop numbness and tingling in the territory of the median nerve when the hands are held in the fully flexed position for 10 minutes or longer. Therefore, if the patient does not experience symptoms within approximately 3 minutes, the test is considered negative.<sup>10</sup>

(continued on page 43)

(from page 40)

Phalen emphasized that the hands must not be forced into flexion by the patient or the examiner during the maneuver.<sup>10</sup> On the contrary, other examiners have used passive and active flexion of the patient's hands during the test, and, in the process, have increased the average amount the hands can be flexed by 20 degrees.<sup>8</sup> Whether this increased flexion affects the outcome of the test is not clear.

### Pathophysiology

The pathophysiology of Phalen's maneuver involves two aspects. First, patients with carpal tunnel syndrome have increased pressure in the carpal tunnel at rest, which is exacerbated by the flexion of the wrist. Second, the nerve fibers in the median nerve are pathologically abnormal, which results from the disease process and contributes to the paresthesia when the nerve is compressed between the transverse carpal ligament and the flexor tendons.<sup>8</sup>

### CLINICAL UTILITY OF TINEL'S SIGN AND PHALEN'S MANEUVER

Although Tinel's sign and Phalen's maneuver are classically associated with carpal tunnel syndrome, their actual utility in the diagnosis has been less clear. Which, if any, of the two tests is better at establishing diagnosis has been debated as well. One study showed that Phalen's maneuver was both more sensitive and more specific than Tinel's sign but that neither was very successful in the diagnosis of carpal tunnel syndrome.<sup>11</sup> This study recommended that all patients with signs and symptoms suggestive of carpal tunnel syndrome be referred for electrodiagnostic testing, the gold standard for diagnosis.

In his original studies, Phalen theorized that Tinel's sign was useful in diagnosing carpal tunnel syndrome. He found a positive Tinel's sign in 73% of 621 hands of patients with suspected carpal tunnel syndrome, but none of these patients had electrodiagnostic confirmation of the diagnosis.<sup>12</sup> Other studies found the sign to be much less prevalent (ie, Tinel's sign was seen in approximately 45% of patients with carpal tunnel syndrome).<sup>13,14</sup> These studies also showed that Tinel's sign was present in over 25% of healthy patients. Additional studies demonstrated ranges of 25% to 75% sensitivity and 70% to 90% specificity for Tinel's sign.<sup>15</sup>

Phalen's maneuver, when performed correctly, also yields varying results in patients with carpal tunnel syndrome. In numerous studies of Phalen's maneuver, the range of positive results in the hands of patients with suspected carpal tunnel syndrome varied from 10% to 88%,<sup>9</sup> with an average of 62%.<sup>8</sup> As with Tinel's sign,

Phalen's maneuver can also be positive in healthy hands, at a rate of approximately 20%. Data have led to sensitivity estimates of 40% to 88% and specificity estimates of 81%.<sup>9</sup> Based upon this, some authors have concluded that Phalen's test may be more useful than Tinel's sign in the diagnosis of carpal tunnel syndrome.

### Electrodiagnostic Examination

In an attempt to determine if the diagnosis of carpal tunnel syndrome can be made clinically or should be confirmed electrodiagnostically, the physical signs have been compared with nerve conduction studies. In one study, 64% of 88 hands of patients with a positive Phalen's test had positive results on electromyography (EMG), whereas 51% of 78 hands of patients with a negative Phalen's test had positive results on EMG.<sup>16</sup> Likewise, 60% of 68 hands of patients with a positive Tinel's sign had positive EMG studies, whereas 55% of 104 hands of patients without a Tinel's sign had positive EMG studies. This data led to the conclusion that clinical signs are not sufficient to make the diagnosis of carpal tunnel syndrome, and electrodiagnostic studies should be used in all cases before surgery is planned.<sup>16</sup>

### SUMMARY

The origin, elicitation, and application of both Tinel's sign and Phalen's maneuver have generated a considerable amount of controversy in the past, and, at present, these tests should only be used in an adjunctive manner in diagnosing carpal tunnel syndrome. Whether electrodiagnostic testing should be universally applied is controversial as well. Regardless, each patient's case must be considered individually to reach the correct diagnosis and appropriate treatment plan. **HP**

### REFERENCES

1. *The Hand: Primary Care of Common Problems*, 2nd ed. New York: Churchill Livingstone, 1990:140-144.
2. Canoso JJ: *Rheumatology in Primary Care*. Philadelphia: WB Saunders, 1997:223-226.
3. Katz RT: Carpal tunnel syndrome: a practical review. *Am Fam Physician* 1994;49:1371-1379.
4. Conn RB, Borer WZ, Snyder JW: *Current Diagnosis*. Philadelphia:WB Saunders, 1997:1012-1017.
5. Alfonso MI, Dzwierzynski W: Hoffman-Tinel sign: the realities. *Phys Med Rehabil Clin N Am* 1998;9:721-736.
6. Moldaver J: Tinel's sign: its characteristics and significance. *J Bone Joint Surg Am* 1978;60:412-414.
7. Clark D: Jules Tinel and Tinel's sign. *Clin Plast Surg* 1983;10:627-628.
8. Seror P: Phalen's test in the diagnosis of carpal tunnel syndrome. *J Hand Surg Br* 1988;13:383-385.
9. Kuschner SH, Ebramzadeh E, Johnson D, et al: Tinel's

- sign and Phalen's test in carpal tunnel syndrome. *Orthopedics* 1992;15:1297-1302.
10. Vargas-Busquets MA: Historical commentary: the wrist flexion test (Phalen sign). *J Hand Surg Am* 1994;19:521.
  11. Kuhlman KA, Hennessey WJ: Sensitivity and specificity of carpal tunnel syndrome signs. *Am J Phys Med Rehabil* 1997;76:451-457.
  12. Phalen GS: The carpal tunnel syndrome: 17 years' experience in diagnosis and treatment of 654 hands. *J Bone Joint Surg Am* 1966;48:211-228.
  13. Stewart JD, Eisen A: Tinel's sign and the carpal tunnel syndrome. *Brit Med J* 1978;2:1125-1126.
  14. Gelmers HJ: The significance of Tinel's sign in the diagnosis of carpal tunnel syndrome. *Acta Neurochir (Wien)* 1979;49:255-258.
  15. Katz JN, Larson MG, Sabra A, et al: The carpal tunnel syndrome: diagnostic utility of the history and physical examination findings. *Ann Intern Med* 1990;112:321-327.
  16. Buch-Jaeger N, Foucher G: Correlation of clinical signs with nerve conduction tests in the diagnosis of carpal tunnel syndrome. *J Hand Surg Br* 1994;19:720-724.

Copyright 2000 by Turner White Communications Inc., Wayne, PA. All rights reserved.